AJMS • Am J Med Surg • December 2020; 2(4). 6-14

Mini invasive surgery for gastro-esophageal junction tumors: An updated review

Edgar Vargas Flores M.D.[1]
Iván González Jiménez M.D.[2]
Victor Manuel Martínez Vargas M.D.[2]
Arturo Benjamin Ortíz Bayliss M.D.[2]
Sonora, Mexico.

Review

ONCOLOGIC SURGERY

OPEN ACCESS

Abstract: While the majority of esophagectomies worldwide are conducted as open procedures, the proliferation of minimally invasive methods is increasing over time. The short-term advantages of minimally invasive esophagectomy in terms of lower morbidity and better quality of life compared to the open approach have become visible in recent years. There are two main approaches in minimally invasive esophagectomy: the transthoracic approach (Accompanied by intrathoracic or cervical anastomosis) or transhiatal esophagectomy (with cervical anastomosis).
MIE (Minimally Invasive esophagectomy) is a healthy procedure with positive oncological outcomes relative to standard open esophagectomy. Minimally invasive surgical techniques are just another therapeutic option for surgical resection of gastroesophageal junction tumors and outcomes are just as good as open procedures when performed by experienced hands.

Keywords: Gastroesophageal junction tumors, Gastroesophageal cancer, Gastric cancer, Minimally invasive esophagectomy, Laparoscopic esophagectomy.

Introduction

Irrespective of the Siewert designation, the surgical treatment of GEJ (Gastro Esophageal Junction) tumors includes the resection of the esophagus and stomach with large margins across the tumor. In general, it is possible to reach at least 5 cm on both proximal and distal margins of the gastroesophageal junction tumor. This margin gap is based on various experiments that have demonstrated that microscopic disease can be found in centimeters away from the body. One research found that patients with gastroesophageal junction tumors with less than 7 positive lymph nodes reported improved survival where the surgical margin was greater than 3.8 cm. Patients with 7 or more positive lymph nodes did not experience the same survival benefit with this surgical margin.[1]

While the majority of esophagectomies worldwide are conducted as open procedures, the proliferation of minimally invasive methods is increasing over time. Ivor Lewis esophagectomy is a procedure that has spread across the world. This review includes a comprehensive assessment of this surgical technique as well as up-to - date results of some worldwide studies on minimally invasive treatment for GEJ (Gastro Esophageal Junction) cancer.

The short-term benefits of minimally invasive esophagectomy in terms of lower morbidity and greater quality of life relative to an open procedure have been evident in recent years. There are two primary approaches to minimally invasive esophagectomy: transthoracic treatment (accompanied by intrathoracic or cervical anastomosis) or transhiatal esophagectomy (accompanied by cervical anastomosis). Controversies exist over the best solution to esophagogastric junction tumors, and the choice of such a solution is actually dependent on the preference of the surgeon. In 2017, Jezerskyte et al.[2] published a report analyzing this particular category of patients: Those with cancer in the esophagogastric junction. While being distal esophagus tumors, tumors arising from the esophageal junction have the peculiarity that they are histologically situated in the transition region from the smooth squamous epithelium of the esophagus to the columnar epithelium of the stomach. It is clear that this transition does not occur specifically in the anatomical transition between the esophagus and the stomach, and thus, despite its drawbacks, the Siewert Classification is used to classify the tumors into three forms: 1. Type I: Adenocarcinoma of the esophagus distal whose center is between 1 to 5 cm above the anatomical esophagogastric junction. 2. Type II: True carcinoma of the cardia that infiltrates from 1cm to the esophageal side and up to 2cm below the esophagogastric junction in the stomach. Type III: Subcardial carcinoma with the center of the tumor between 2 and 5 cm below the esophagogastric junctionAccording to this classification, each tumor will be approached and treated. Siewert I and II tumors are classified and staged using the esophageal cancer regime, while in Siewert III tumors the gastric cancer

1. Department of General Surgery / Laparoscopic surgery at Hospital General de Zona 5. IMSS. Sonora, Mexico. 2. Department of Oncologic surgery at Hospital General de Zona 5. IMSS. Sonora, Mexico. *Received on December 4, 2021. Accepted on December 10, 2021. Published on December 17, 2021.*

 DOI: 10.17605/OSF.IO/WXPYD

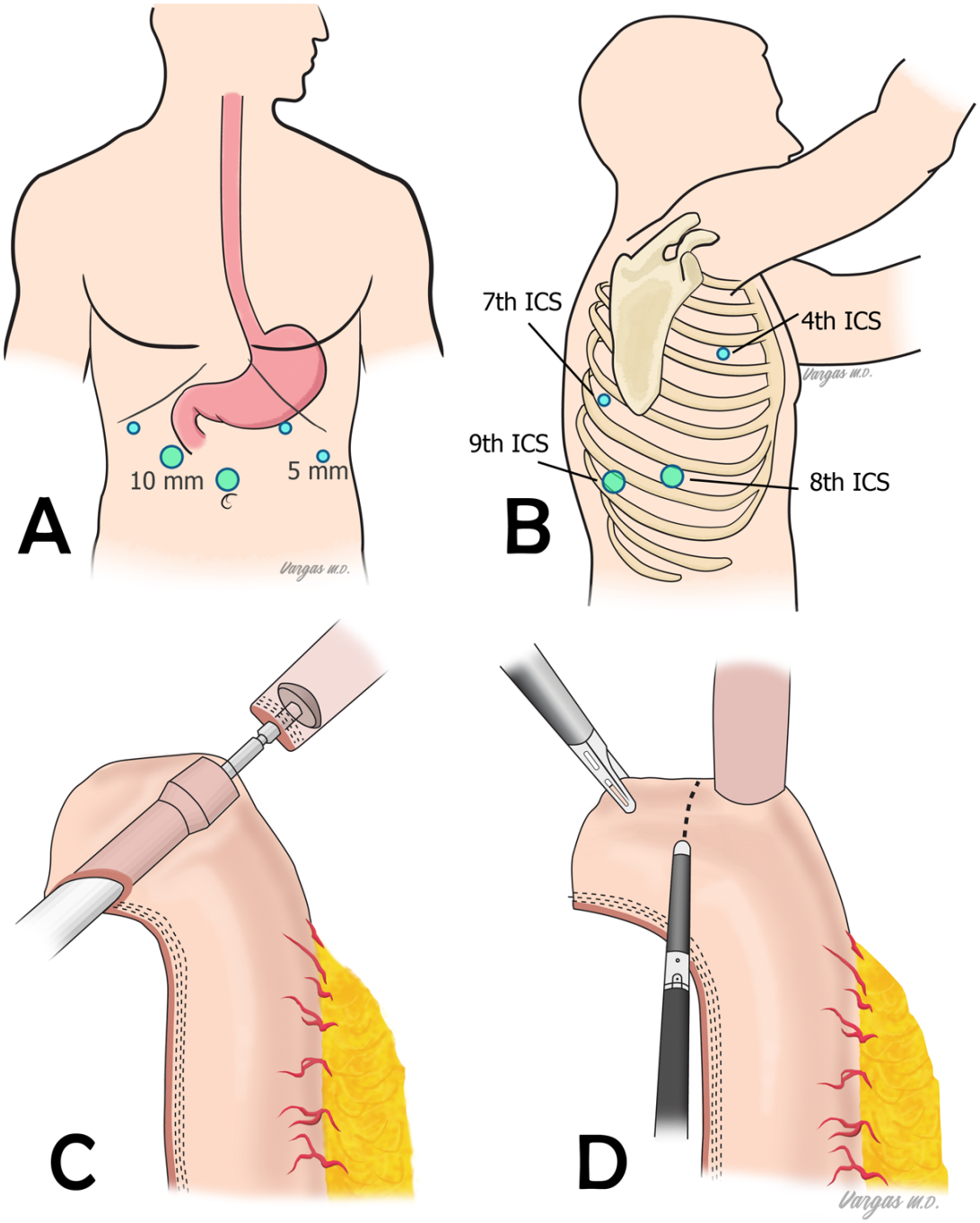

Figure 1. Surgical technique in minimally invasive Ivor Lewis Esophagectomy. A: Trocars positioning in abdominal procedure; B: Trocars positioning in thoracic procedure; C: Esophago-gastric anastomosis with a circular stapler; D: Completion of esophago-gastric anastomosis.

regime is used, even if the esophageal cancer junction is involved. After neoadjuvant therapy, there are three main approaches to tumor resection of the esophagogastric junction: transthoracic esophagectomy (Ivor-Lewis or McKeown), transhiatal esophagectomy (Orringer) or total gastrectomy. The decision on the surgical approach is at the discretion of the surgeon and, while numerous trials have taken place globally, there is still no credible proof on the correct approach in terms of morbidity and oncological outcomes to date. Laparoscopic gastrectomy is usually performed for tumors of Siewert III. The minimally invasive Ivor-Lewis treatment (although some suggest cervical anastomosis) is used with Siewert II tumors. There is a substantial growth in the use of this method each year, with the one used in 41% of esophageal resections in the Netherlands in 2015. This technique involves intrathoracic anastomosis in the prone posture after laparoscopic preparation of the gastric tract and thoracoscopic resection of the esophagus. Some surgeons use minimally invasive transhiatal esophagectomy with cervical anastomosis. This method has drawbacks due to the failure to perform mediastinal lymphadenectomy and is intended for vulnerable patients with distal tumors or esophagogastric junction. For cases where there is extensive tumor development at a lower curvature, an

DOI: 10.17605/OSF.IO/WXPYD

open esophageal and gastric resection accompanied by a conversion of the colon is performed. The same minimally invasive esophagectomy is suggested in the tumors with Siewert I. The key issue is that whatever technique you choose, the resection should be R0. The advantages of minimally invasive esophagectomy in the treatment of esophagogastric junction cancer compared to open-label treatment are improvements in short-term outcomes, such as reduced bleeding, lower respiratory infection and improved post-surgical quality of life, with similar survival rates for 1 and 3 years. In a non-randomized study , patients with intrathoracic anastomosis showed better functional outcomes than the cervical anastomosis group with lower dysphagia, lower benign stenosis and lower incidence of recurrent laryngeal nerve palsy. In the experience of the Dutch community with intrathoracic anastomosis followed by the "Flap & Wrap" procedure, the rate of leakage of anastomosis was reduced to 5 per cent while the rate of leakage remained 20 per cent in patients with cervical anastomosis. In fact, more extensive lymphadenectomy may be done in transthoracic surgery relative to transhiatal or gastrectomy, and nodal status appears to be a significant indicator of survival.[2]

Pre-op preparation

As with any oncological patient, extensive pre-op staging is required for patient selection and surgical strategy, including computed tomography and/or endoscopic ultrasound, flexible bronchoscopy and PET scan when necessary. The assessment of functional status, nutritional status and comorbidities is necessary before considering any surgical procedure or multidisciplinary treatment. Preparation for surgery should include smoking abstinence, daily walking and use of an incentive incentive spirometer and a week of preoperative enteral nutrition for patients with long-lasting dysphagia and significant weight loss.

Surgical technique

General anesthesia should be administered using a double-lumen endotracheal tube. After the abdomen is prepped and draped, a 10-mm port is placed in the epigastric area for the camera. Another 10-mm port is placed in the right epigastric area, approximately 1 handbreath away from the camera port. Two 5-mm ports are placed in the right upper quadrant, with the port furthest to the patient's right side acting as the liver retractor **(Figure 1 A)**. One 5-mm port is placed in the left upper quadrant. Dissection should begin with division of the gastrohepatic ligament. This division should be performed with an energy device such as an ultrasonic scalpel instrument. Rarely, an accessory left hepatic vessel may course through this ligament. This dissection should proceed to the level of the right crus of the diaphragm. At this point the left gastric pedicle can be dissected as well. Next, the greater curvature is mobilized by dividing the gastrocolic and gastrosplenic ligaments, and the short gastric vessels that course along this area. At least 40 to 50% of the greater curvature should be mobilized to ensure adequate length of the gastric conduit. When retracting along the greater curvature, excessive force can lead to splenic injury and significant bleeding and possibly the need for a splenectomy. The principal blood supply of the gastric conduit is the right gastroepiploic artery and care must be taken to preserve this artery and prevent damage to it during the dissection of the greater curvature. During the dissection, the energy device should be no closer than several millimeters away from the gastroepiploic artery, to prevent inadvertent thermal damage to the artery. Injury to the right gastroepiploic artery may lead to gastric conduit necrosis, a condition associated with high morbidity and mortality. Once the lesser and greater curvatures have been mobilized, the esophagus and gastroesophageal junction are encircled. With this maneuver, the left gastric pedicle should be fully isolated. The left gastric pedicle can then be divided with a vascular stapling device. The stapler should be placed as close to the retroperitoneum as possible, to allow for as wide a lymph node retrieval as possible in this area. The gastric conduit should then be divided after the orogastric tube has been removed. In is recommended to make the conduit approximately 4 to 5 cm in width.[1] The specimen is then temporarily sutured to the distal esophagus, to allow delivery of the stomach into the chest during the thoracic portion of the operation. A Kocher maneuver is then performed to ensure adequate length of the conduit. There are different strategies used to address gastric emptying across different centers. At the author's institution, a pyloromyotomy is performed. Many centers alternatively perform a pyloroplasty, injection of botulinum toxin into the pylorus longitudinally for approximately 4 cm, centered across the pylorus. The muscle layer is then closed transversely, thereby avoiding excessive narrowing of the pylorus. A jejunal feeding catheter should be considered to be placed in all cases, because the patient may require supplemental nutrition for several weeks before oral intake can meet metabolic demands. The port furthest to the patient's left side is used as the insertion site for the catheter, to avoid an additional puncture through the abdomen, and a 14-French soft red rubber catheter is used as the tube. Each of the 10-mm ports has its fascia closed prior to skin closure. Four small incisions

DOI: 10.17605/OSF.IO/WXPYD

are made in the chest. The camera is inserted in the midaxillary line through a 1-cm incision at the seventh or eighth intercostal space, depending on the patient's body habitus. A posterior 1-cm incision in the eighth intercostal space is created for retraction. A 1-cm incision is created anteriorly in the sixth intercostal space at the anterior axillary line. Finally, a 1-cm incision is created anteriorly in the fourth intercostal space at the anterior axillary line **(Figure 1 B)**. The inferior pulmonary ligament is divided and the lung is retracted anteriorly. With the patient rotated slightly anteriorly, the lung should retract without the need of an additional lung retractor of any kind. The pleura overlying the esophagus is divided and the esophagus is encircled. A pliable Penrose drain can be placed around the esophagus and used for retraction or the esophagus can be grabbed directly if care is taken not to tear it. The dissection of the esophagus should proceed to the level of the azygous vein. Direct feeding vessels from the aorta should be divided using an energy device. Mediastinal lymph nodes in the inferior pulmonary ligament, paraesophageal area, and subcarinal regions should be dissected and sent for pathologic review. The azygous vein should be encircled and divided using a vascular stapler. The esophagus is then divided at approximately the level of the azygous vein. The gastric conduit should be pulled completely into the chest to make sure there is adequate length before deciding on the proximal division point. The specimen is placed into an impermeable plastic or mesh bag, to prevent port site implantation of tumor. The incision with the camera is then lengthened to allow for removal of the specimen. To perform the anastomosis a small gastrotomy is made, close to the tip of the gastric conduit and just large enough to allow a circular 25-mm stapler to fit. The accepting anvil can be placed transorally by the anesthesia team and passed down to the staple line on the esophagus **(Figure 1 C)**. A small hole, just large enough to accept the anvil, is then created on the esophagus. The hole should be created within 2 mm to 3 mm of the staple line but not on the staple line directly. The anastomosis is then performed in end-to-side fashion. The gastrotomy and excess stomach are divided using a linear stapler **(Figure 1 D)**. The author's practice is to perform an esophagogastroscopy after the stapling to assess the anastomosis and to place a nasogastric tube in the appropriate position. Most patients should not need to go to the intensive care unit postoperatively. If the tumor involves a large amount of the stomach or the stomach cannot be used for any particular reason, the colon is an excellent alternative as a conduit. The authors preferred approach is to use the ascending colon in an isoperistaltic fashion. The colon is routed substernally and the proximal anastomosis performed between the esophagus and the colon. The distal anastomosis is between the colon and the remaining stomach, or a Roux-en-Y jejunal limb can be used if the entire stomach has to be resected.

Postoperative care

Tube feeds can be begun early in the postoperative course as the patient recovers and the esophagogastric anastomosis heals. A gastrograffin swallow should be performed on postoperative days 5 to 7, although many centers do not routinely perform this test. Most patients can be discharged home with a soft oral diet and maintenance tube feeds. An anastomotic leak after an Ivor Lewis esophagectomy can be a fatal complication if not recognized early but in most cases can be treated with minimal morbidity to the patient. Tachycardia is often the firs presenting sign of an anastomotic leak. Fever and rising white blood cell count can accompany an anastomotic leak as well. Diagnosis should be made with a gastrograffin swallow and confirmed with esophagoscopy. Once recognized, placement of an esophageal stent across the anastomosis often resolves most cases. Any pleural effusion that has accumulated should be drained by tube thoracostomy. Overall the incidence of anastomotic leak has decreased significantly over the past 2 decades, and the average incidence of anastomotic leak after Ivor Lewis esophagectomy is approximately 3%. Although rare, chylothorax can be a persistent and burdensome complication of esophagectomy. An increased amount of drainage from the chest tube, especially after initiation of jejunal feeds or an oral diet, can be the first sign of chylothorax. Classically the character of the chest tube drainage is thin, milky fluid, but the chest tube drainage can also be serous. Measurement of the triglyceride level is diagnostic, with levels usually greater than 500 mg/dL. Initial treatment should be cessation of diet and total parenteral nutrition. A low-fat diet can be maintained if chest tube drainage does not drain excessive. If these initial measures do not work, then surgery to ligate the thoracic duct may be necessary. At many centers, the interventional radiology team may be able to perform a thoracic duct embolization percutaneously using lymphoscintigraphy.[1]

Outcomes

Variation and combination of open (or hand assisted) esophagectomies provide and increased array of surgical modalities in the treatment of this malignancy. MIE is a safe operation with similar oncologic outcomes when compared with traditional open esophagectomy. As technology improves with

DOI: 10.17605/OSF.IO/WXPYD

the concurrent advancement of critical care and postoperative management, the complication risk of MIE has decreased significantly.[3] Recently, reported randomized trials suggest that minimally invasive approaches do reduce the morbidity of esophagectomy and therefore become the optimal management for many patients. In-hospital pulmonary infections were reduced from 34 to 12% but with no difference in mortality.[4] Minimally invasive esophagectomy includes two techniques: thoraco-laparoscopic esophagectomy in three stages (a modification of the classic operation of McKeown where right thoracotomy is replaced by thoracoscopy and laparoscopy), and minimally invasive transhiatal esophagectomy (a modification of esophagectomy classic 2-stage transhiatal procedure), where laparotomy is replaced by laparoscopy.[5] Cuschieri and colleagues were the first to report minimally invasive esophagectomy in 5 patients in 1992. In this series, the esophagus was mobilized by video-assisted thoracic surgery (VATS). This study was followed by some reports on minimally invasive techniques for esophageal resection. Collard and colleagues in 1993 and McAnena and colleagues also reported a thoracoscopic resection while DePaula et al. Reported a transhiatal resection in 1995. The clinical results in these early reports were inconclusive. In 2003, Luketich et al. Reported the first series of cases with minimally invasive esophagectomy and showed an impressive low morbidity and mortality in 222 patients. The 30-day mortality rate was 1.4% and the pneumonia rate was 7.7%. The first report of minimally invasive esophagectomy in the prone position in a large cohort of patients was published by Palanivelu et al. They showed 30-day mortality and pneumonia in 130 patients of around 1.54%. Following these promising results, the minimally invasive esophagectomy began to slowly gain acceptance.[6] Open transthoracic esophagectomy (Ivor Lewis procedure or Akijama procedure) is associated with significant morbidity (60 to 80%) and an operative mortality rate of 5% to 10%. To reduce these complications, transhiatal esophagectomy with esophagogastric cervical anastomosis (Orringer's procedure) has been suggested by some authors. The results of comparing the transthoracic and transhiatal approaches have been controversial.[7] This surgical procedure has a high incidence of postoperative complications, especially pulmonary infections and is associated with a lower quality of life. Minimally invasive procedures are increasingly implemented to reduce such complications and improve postoperative quality of life. Minor pulmonary infections are reported after minimally invasive esophagectomy as well as better pain tolerance, lower blood loss and shorter in-hospital stay. The quality of life after an open transthoracic esophagectomy improves within the first year, however studies that investigate quality of life after a minimally invasive procedure show conflict in their results because they are based on serial analysis of patients and not in randomized studies.[8] Of a total of 114 patients studied in Japan by Hong et al. 59 patients were enrolled in the open esophagectomy group and 55 patients in the minimally invasive esophagectomy group. The incidence of pulmonary morbidity was 9.09% and vocal cord paralysis was 0% in the minimally invasive surgery group, both results were significantly different against the open procedure. In addition, in the group of minimally invasive surgery, postoperative quality of life was better than in the open surgery group. Minimally invasive esophagectomy could lead to a significant improvement in short-term benefits for patients with type I esophagogastric junction adenocarcinoma of Siewert.[9] In this retrospective series by Glatz et al. 60 patients were analyzed in whom the minimally invasive hybrid laparoscopy-torcoscopy technique was used and paired with patients operated with an open technique to make a comparison. There was no difference in the harvested lymph nodes (22 vs 20, $p = 0.459$) and the R0 resection rate (95% vs 93%, $p = 0.500$). The operative time was significantly shorter for the minimally invasive technique (329 vs 407 minutes, $p < 0.001$). There was no difference between the groups regarding surgical complications (37 vs 37%, $p = 0.575$), but patients operated under the minimally invasive technique had more delayed gastric emptying (23% vs 10%, $p = 0.042$). Lung morbidity was significantly decreased with the minimally invasive technique (20% vs 42%, $p = 0.009$). The difference in the overall complication rate was not significant (50% vs. 60%, $p = 0.179$), but the complications that endangered life (Clavien-Dindo 4/5) were less frequent 2% vs 12%, $p = 0.031$). In general, there was a significantly lower need for transfusion after the minimally invasive technique (18% vs 50%, $p < 0.001$) and the hospital stay was significantly shorter (14 vs 18 days, $p = 0.002$). The multivariate analysis showed the surgical procedure as an independent risk factor for the development of pulmonary complications (OR 3.2, $p = 0.011$). Concluding that the procedure is safe and the rate of complications and oncological radicality are comparable to the conventional procedure.[10] Luketich and colleagues conducted a phase II, multicenter, prospective study to evaluate the feasibility of minimally invasive esophagectomy. Patients from 17 institutions were enrolled with a confirmatory biopsy of high-grade dysplasia or esophageal cancer. The surgical protocol consisted of a minimally invasive esophagectomy of three fields or an Ivor Lewis minimally invasive esophagectomy. The primary

DOI: 10.17605/OSF.IO/WXPYD

objective was to assess the 30-day mortality. Secondary objectives were the analysis of adverse events, hospital stay and 3-year outcomes. The surgical protocol was completed in 95 of 104 patients eligible for primary analysis (91.3%). The 30-day mortality in the eligible patients in whom minimally invasive esophagectomy was performed was 2.1%; Perioperative mortality in all registered patients eligible for primary analysis was 2.9%. The median stay in intensive and hospital therapy was 2 and 9 days respectively. Events grade 3 or higher included anastomotic leak (8.6%), acute respiratory distress syndrome (5.7%) pneumonitis (3.8%) and atrial fibrillation (2.9%). At a median follow-up of 35.8 months, the estimated 3-year global survival was 58.4% (95% CI: 47.7% -67.6%). The loco-regional recurrence occurred only in 7 patients (6.7%).[11] Laparoscopic wide resection is widely performed to treat submucosal gastric tumors. Despite the development of novel procedures such as laparoscopic-endoscopy cooperative surgery (LECS) and Non-exposed endoscopic wall-inversion surgery (NEWS), the most appropriate surgical intervention for gastric submucosal tumors remains uncertain. Shoji et al. Retrospectively reviewed patient characteristics, surgical outcome, postoperative courses, histopathological results and costs of 71 consecutive patients in whom laparoscopic resection, LECS and NEWS were performed to treat gastric submucosal tumors from January 2010 to June 2016. Extensive resection, LECS and NEWS were performed in 31, 14 and 26 cases respectively. The characteristics of the patients were comparable between the three groups. Wide laparoscopic resection was not performed in tumors of the esophagogastric junction to avoid postoperative strictures and LECS was not performed in ulcerated tumors to avoid tumor spread. NEWS was considered for tumors smaller than 3 centimeters for trans oral extraction. The specimen resected by laparoscopic wide resection was significantly larger than in the other groups. The laparoscopic wide resection group had a higher complication rate. Compared with the LECS group, the postoperative C reactive protein was significantly lower as well as the hospitalization time in the NEWS group. The surgical procedure for the treatment of submucosal gastric tumors should be chosen carefully according to the tumor size, location and presence or absence of ulceration. For selected patients, the NEWS seems to be appropriate for the treatment of these tumors.[12] Other alternatives to a minimally invasive approach is the use of 3D lenses that have been introduced gradually. In a study conducted by Charalabopoulos et al. A total of 13 patients (mean age 67.4) underwent minimally invasive esophagectomy for adenocarcinoma of the distal esophagus or the gastric esophageal junction between January and September 2016. The resection was performed in the prone position, and a termino-lateral gastro-esophageal knotless anastomosis was constructed. The 2D approach was used in 10 patients (77%) and 3D in 3 patients (23%). Eight patients (61.5%) had neoadjuvant chemotherapy and 5 (38.5%) had primary surgery. The mean surgical time was 420 minutes and the average number of days of hospital stay was 10 days without associated mortality. One patient (1.7%) developed radiological evidence of anastomotic leak that did not require intervention. The thoracoscopic approach based on 3D lenses, using 100° angulated tip allowed a clearly superior visualization for an accurate lymphadenectomy in combination with the safe and efficient construction of the anastomosis. The knotless anastomosis technique was efficient and safe with promising results in the short term. The 3D approach seems to be superior when performing the anastomosis than the 2D approach. However, studies with a larger number of patients are required to demonstrate this superiority.[13] Minimally invasive esophagectomy has proven to be a feasible technique for the treatment of esophageal cancer; however, its postoperative morbidity continues to be high. A retrospective study was conducted to evaluate the effect of postoperative complications on long-term outcomes in patients who underwent minimally invasive esophagectomy for squamous cell esophageal carcinoma. The study included patients in whom the technique was performed between September 2009 and November 2014; All procedures were performed by the same surgical team. The relevant characteristics of the patients were collected and the postoperative variables were analyzed and evaluated. Disease-free survival and disease-specific survival were determined with the Kaplan-Meier method and compared by log-rank. The possible predictors of survival were evaluated in univariate and multivariate form by Cox regression analysis. A total of 240 patients were analyzed, including 170 men and 40 women. All patients underwent thoracoscopic or laparoscopic-thoracoscopic esophagectomy. One hundred and thirty patients (60.7%) had postoperative complications. Disease-free survival and disease-specific survival was 80% and 88.9% at one year, 48.6% and 54.2% at three years, and 43.2% and 43.5% at five years. Univariate analysis and risk ratio analysis showed that T stage, N stage and tumor grade were independent prognostic factors for long-term survival; however, postoperative complications had no significant effect on disease-free and disease-specific survival in this cohort of patients (log-rank, $p = 0.354$ and 0.160 respectively). It was concluded that postoperative morbidity has no significant effect on long-term survival in patients who

DOI: 10.17605/OSF.IO/WXPYD

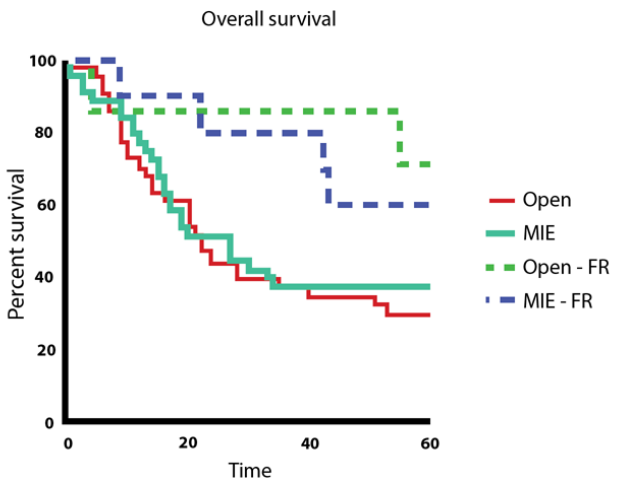

Figure 2. Kaplan-Meier curves for comparison of overall survival between open and minimally invasive esophagectomy (FR, full responders with no residual tumor). This figure is reproduced with permission from Palazzo F et al.[16]

underwent minimally invasive esophagectomy for squamous cell carcinoma.[14] In 2015, Mu et al. Performed a retrospective study that included 375 patients undergoing esophagectomy with a Mckewon minimally invasive technique, 70 of those patients treated by hybrid surgery and 103 of them treated by the Mckewon technique. The minimally invasive technique demonstrated a less transoperative bleeding (100ml vs 300ml p = 0.001) and comparable survival (5-year survival 60.5% vs 47.9% p = 0.735).[15] In 2015, Palazzo et al. Compared esophagectomy using a minimally invasive approach with an open or hybrid approach, noting that the oncological efficacy between the two techniques had previously been similar (evaluated by harvesting lymph nodes and number of lymph nodes in R0 resections) and showed that the minimally invasive approach was associated with less bleeding (125 vs 300mL, p <0.01), shorter in-hospital stay (8 vs 15.5 days, p <0.01), higher nodal harvest (median, 21 vs 10, p <0.01), and, after adjusting the variables, better median survival (Not reached vs 36.3 months, 95% CI: 18.1, 53.9), better overall survival at 5 years (64.3 vs 34.7%, p <0.001). And a double risk of death associated with an open or hybrid approach (HR = 2.00, 95% CI 1.12, 3.57, p = 0.019) **(Figure 2)**.[16] Straatman et al demonstrated, through a randomized and multicenter prospective clinical trial, that there are no statistically significant differences between open esophagectomy (right thoracotomy with selective intubation and laparotomy with cervical or thoracic anastomosis) and minimal invasion (right thoracoscopy in prone position with endotracheal tube of a lumen and laparoscopy with cervical or thoracic anastomosis) in relationship to disease-free and global survival at 3 years (37.3% vs. 42.9%, P = 0.602 and 41.2% vs. 42.9%, P = 0.633, respectively) with a similar rate of local recurrences and postoperative distant metastases between both techniques (p = 0.258). These results were maintained even after stratifying the analysis by the TNM staging system, so when performing the regression analysis it was found that the surgical approach did not affect survival. In addition to being a study with a rigorous design and high level of evidence, 32 (54%) and 31 (55%) patients with tumors in the lower third of the esophagus and the esophagogastric union in the minimally invasive surgery arm were included and open arm respectively. Regarding the morbidity and mortality of each procedure, the minimally invasive approach was associated with less bleeding (median, 200 vs 475 mL, p <0.001), lower number of lung infections (9 vs 29%, p = 0.005 at 2 weeks and 12 vs 34%, p = 0.005 during hospitalization), although there was no difference in 30-day mortality (p = 0.329). This essay, although it seems to exclude all selection biases, is far from perfect. The number of patients included was relatively small (59 and 56 patients per group), the median follow-up was 22 and 27 months and not 5 years as would be expected in a survival study.[17] In 2016, Scarpa et al. Conducted a case-control study in which the minimally invasive hybrid technique of esophagectomy was compared with the open approach, evaluating the impact on post-surgical inflammatory and nutritional status, measured through C-reactive protein, albumin and the leukocyte count. The evaluation included 34 cases operated with a minimally invasive hybrid approach (Thoracoscopy, laparoscopy ± cervicotomy) and were matched with 34 controls operated by an open approach (Ivor-Lewis in tumors of the mid-distal third and of the esophagogastric junction and McKeown in third tumors). To evaluate the systemic inflammatory response, blood samples were taken on days 1, 3 and 7 after surgery and the leukocyte count, C-reactive protein and albumin were analyzed. Both groups were similar in the demographic variables and tumor characteristics. Regarding postsurgical results, these were also similar in terms of the complication rate (32.4% in the control group and 29.4% in the cases, p = 0.99). The ICU stay was shorter in patients in the case group (3 [2-3] vs 2 [1-2] days, p = 0.002). On the first postoperative day, patients in the case group had lower levels of C-reactive protein (median 61.0 [IQR: 51.8-78.0] vs. 84.2 [69.3-100.0] in the open group, P = 0.001) and leukocyte count (median 8780 [IQR: 7300-10510] vs. 10530 [7710-12300] in the open group, P = 0.05) and a higher albumin level (median 31.0 [IQR: 29.0-34.0] vs. 28.0 [25.0-31.0] in the open group, P = 0.001) which persisted elevated also on days 3 (P = 0.06) and 7 (P = 0.008). The levels of C-reactive protein were similar to day 7, while those of the leukocyte count were similar on day 3 and 7 **(Figure 3)**. It is concluded that the relative preservation of the immune competence and the lower response to

DOI: 10.17605/OSF.IO/WXPYD

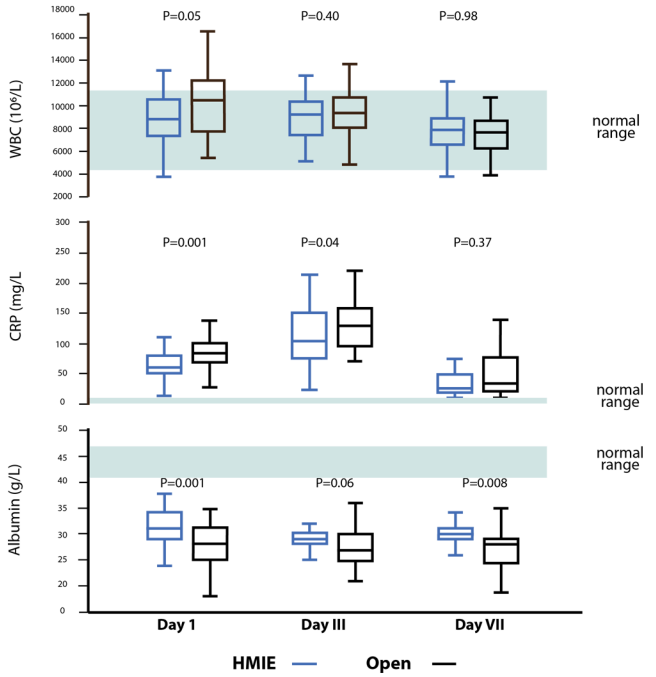

Figure 3. Postoperative systemic inflammation and nutritional status at 1, 3 and 7 post operative days in laparoscopy (HMIE) and laparotomy (open) groups, CRP, C-reactive protein, HMIE, hybrid minimally invasive esophagectomy; WBC, white blood cell count. This figure is reproduced with permission from Straatman J et al.[17]

surgical stress that occurs during minimally invasive surgery explains the short-term advantages of these procedures. It was observed that the minimally invasive hybrid surgery for cancer significantly improves the systemic inflammatory response and catabolic response to surgical trauma, contributing to a shorter stay in the ICU. Quality of life and final esophageal function were comparable in both groups.[18] Esophageal resection for cancer continues to be the gold standard, not only for the possibility of cure but for palliation of dysphagia. However, to date there has been no clear evidence that avoiding thoracotomy with a transhiatal approach to resect the esophagus improves the results in relation to the survival of the disease. The extent of lymphadenectomy remains controversial. Those who promote open procedures for esophageal resection strongly recommend mediastinal lymphadenectomy, while proponents of the transhiatal approach hold the opinion that a more extensive lymphadenectomy does not influence survival. A minimally invasive approach to esophageal resection seems to offer the potential for a more radical approach to mediastinal resection, compared with transhiatal esophagectomy. In experienced hands, a minimally invasive esophageal resection is a safe option. It has been demonstrated that the pathological and oncological results are not affected using a minimally invasive procedure compared to an open procedure. Minimally invasive techniques to resect the esophagus in patients with cancer are safe and comparable to an open approach with respect to postoperative recovery and cancer survival.[2] In 2017, Mu and cols performed a retrospective study comparing short-term results and 3-year survival among 151 patients undergoing open McKewon esophagectomy with two incisions and 361 with the same technique using a minimally invasive approach, of these 10 (8.7 %) patients of the first group and 42 (11.6%) patients of the second group corresponded to tumors of the lower third of the esophagus and the esophagogastric junction. Despite requiring more surgical time (310 vs 345 minutes p = 0.002) and causing greater hospital expenditure (¥ 65,600 vs. ¥ 103,000; P <0.001), esophagectomy with a minimally invasive approach was associated with less bleeding (191mL vs 287mL, p <0.001), shorter hospital stay (20 days vs 23 days, p = 0.025) and similar survivals (3-year global survival 64.1% vs. 73.8%, P = 0.101) 3-year recurrence-free survival 78.8% vs. 97.2%, P = 0.314); However, when performing the pairing of the variables, a trend towards a better global and disease-free survival was reported in favor of the group with the minimally invasive approach (64.1% vs. 79.5%, P = 0.063 and 65.3% vs. 82.8% ; P = 0.058 respectively) although these results should be taken with moderation because despite there being no significant differences, the open-access group did have a greater number of patients with locally advanced tumors (T4).[19]

Conclusion

Minimally invasive surgical techniques are just another therapeutic option for surgical resection of gastro esophageal junction tumors. There is reasonable evidence that open vs. minimally invasive approaches offer similar complication rates and survival in surgical centers with high level of expertise in laparoscopic oncologic surgery.

Conflicts of interests

The authors have no conflicts of interest to declare.

References

1. Okereke IC. Management of Gastroesophageal Junction Tumors. Surg Clin North Am. 2017 Apr;97(2):265-275.
2. Jezerskyte E, van Berge Henegouwen M, Cuesta M, Gisbertz S. Gastro-esophageal junction cancers: what is the best minimally invasive approach? J Thorac Dis 2017;9(Suppl 8):S751-S760.
3. Wiesel O, Whang B, Cohen D, Fisichella PM. Minimally Invasive Esophagectomy for Adenocarcinomas of the Gastroesophageal Junction and Distal Esophagus: Notes on Technique. J Laparoendosc Adv Surg Tech A. 2017 Feb;27(2):162-169.

DOI: 10.17605/OSF.IO/WXPYD

4. Kleinberg L, Brock M, Gibson M. Management of Locally Advanced Adenocarcinoma of the Esophagus and Gastroesophageal Junction: Finally a Consensus. Curr Treat Options Oncol. 2015 Jul;16(7):35. doi: 10.1007/s11864-015-0352-6.
5. Bonavina L, Asti E, Sironi A, Bernardi D, Aiolfi A. Hybrid and total minimally invasive esophagectomy: how I do it. J Thorac Dis. 2017 Jul;9(Suppl 8):S761-S772. doi: 10.21037/jtd.2017.06.55.
6. Wullstein C, Ro-Papanikolaou H-Y, Klingebiel C, Ersahin K, Carolus R. Minimally Invasive Techniques and Hybrid Operations for Esophageal Cancer. Visceral Medicine. 2015;31(5):331–6.
7. Braghetto I, Csendes A, Cardemil G, Burdiles P, Korn O, Valladares H. Open transthoracic or transhiatal esophagectomy versus minimally invasive esophagectomy in terms of morbidity, mortality and survival. Surgical Endoscopy. 2006 Jun;20(11):1681–6.
8. Maas KW, Cuesta MA, Henegouwen MIVB, Roig J, Bonavina L, Rosman C, et al. Quality of Life and Late Complications After Minimally Invasive Compared to Open Esophagectomy: Results of a Randomized Trial. World Journal of Surgery. 2015Mar;39(8):1986–93.
9. Hong L, Zhang Y, Zhang H, Yang J, Zhao Q. The Short-Term Outcome of Three-Field Minimally Invasive Esophagectomy for Siewert Type I Esophagogastric Junctional Adenocarcinoma. The Annals of Thoracic Surgery. 2013;96(5):1826–31.
10. Glatz T, Marjanovic G, Kulemann B, Sick O, Hopt UT, Hoeppner J. Hybrid minimally invasive esophagectomy vs. open esophagec tomy: a matched case analysis in 120 patients. Langenbecks Arch Surg. 2017 Mar;402(2):323-331. doi: 10.1007/s00423-017-1550-4. Epub 2017 Jan 12.
11. Luketich JD, Pennathur A, Franchetti Y, Catalano PJ, Swanson S, Sugarbaker DJ et al. Minimally invasive esophagectomy: results of a prospective phase II multicenter trial-the eastern cooperative oncology group. Ann Surg. 2015 Apr;261(4):702-7. doi: 10.1097/SLA.0000000000000993.
12. Shoji Y, Takeuchi H, Goto O, Tokizawa K, Nakamura R, Takahashi T et al. Optimal minimally invasive surgical procedure for gastric submucosal tumors. Gastric Cancer. 2018 May;21(3):508-515. doi: 10.1007/s10120-017-0750-5. Epub 2017 Jul 25.
13. Charalabopoulos A, Lorenzi B, Kordzadeh A, Tang CB, Kadirkamanathan S, Jayanthi NV. Role of 3D in minimally invasive esophagectomy. Langenbecks Arch Surg. 2017 May;402(3):555-561. doi: 10.1007/s00423-017-1570-0.
14. Li KK, Wang YJ, Liu XH, Tan QY, Jiang YG, Guo W. The effect of postoperative complications on survival of patients after minimally invasive esophagectomy for esophageal cancer. Surg Endosc. 2017 Sep;31(9):3475-3482. doi: 10.1007/s00464-016-5372-1.
15. Mu JW, Gao SG, Xue Q, Mao YS, Wang DL, Zhao J, et al. The impact of operative approaches on outcomes of middle and lower third esophageal squamous cell carcinoma. World J GAstroenterol. 2015;21(45): 12873-81
16. Palazzo F, Rosato EL, Chaudhary A, Evans NR, Sendecki JA, Keith S, et al. Minimally Invasive Esophagectomy Provides Significant Survival Advantage Compared to Open or Hybrid Esophagectomy for Patients with Cancers of the Esophagus and Gastroesophageal Junction. J Am Coll Surg. 2015;220(4):672-9.
17. Straatman J, van der Wielen N, Cuesta MA, Daams F, Roig Garcia J, Bonavina L, et al. Minimally Invasive Versus Open Esophageal Resection: Three-year Follow-up of the Previously Reported Randomized Controlled Trial: the TIME Trial. Ann Surg. 2017; 266(2):232-236
18. Scarpa M, Cavallin F, Saadeh LM, Pinto E, Alfieri R, Cagol M, et al. Hybrid minimally invasive esophagectomy for cancer: impact on postoperative inflammatory and nutritional status. Dis Esophagus. 2016; 29(8):1064-1070
19. Mu JW, Gao SG, Xue Q, Mao YS, Wang DL, Zhao J, et al. Comparison of short-term outcomes and three year survival between total minimally invasive McKeown and dual-incision esophagectomy. Thoracic Cancer, 2017;8(2):80-87

Edgar Vargas Flores
General Surgery/Laparoscopy
Hospital General de Zona 5
Sonora, Mexico
eddgar868@gmail.com

DOI: 10.17605/OSF.IO/WXPYD