AJMS • Am J Med Surg • October 2022; 9(3). 1-4

Free vascularized fibula flap for forearm reconstruction. A case report

Abdulwahab Olarenwaju Ajani M.D.
Christian Chukwudi Ojidoh M.D.
Oluwaseyi Kayode Idowu M.D.
Taiwo Olusola Osisanya M.D.
Opeyemi Idris Olusanmade M.D.
Mahamud Abiodun Lawal M.D.
Opeyemi Muyiwa Oyewande M.D.
Mustapha Faiz Alimi M.D.

Lagos, Nigeria

Case report

Plastic Surgery

OPEN ACCESS

Background: Bony defects caused by tumour resection, infection or trauma poses a major challenge for the reconstructive team. Limb sparing is possible in a majority of these patients with numerous options in literature and is currently the treatment of choice. In Low and Middle-Income countries, the options are limited by their cost and available expertise. This case report highlights the use of a vascularized free fibular graft for forearm reconstruction following tumour resection in our institution.
Case Report: Mrs A.O, a 39-year-old school teacher who had wide local excision of a mass arising from the distal two-thirds of the right radius. The histopathology confirmed a giant cell tumour and had a defect measuring 20cm in the radius and 4cm of the distal ulnar which was bridged with a vascularized fibular and non-vascularized fibular graft respectively.
Conclusion: Autologous free vascularized fibular grafts (FVFG) are a valuable option for reconstructing large bony defects in resource-poor settings and have the potential for reduced complications as compared to other advanced methods.

Keywords: bone defects, vascularized fibular graft, microsurgery

There has been a significant advancement in the treatment of tumours of the upper extremity with a wide range of reconstructive options now available aimed at maintaining limb length and offering acceptable cosmetic and functional outcomes[1]. Skeletal reconstruction of large tumour resection defects is challenging with free vascularized fibular transfer offering the potential for rapid autograft incorporation[2]. The fibula is an expendable bone in the lower limb with approximately 25cm available for harvest. It has a reliable pedicle length averaging 6cm with a diameter of 2-3mm, blood supply via the nutrient artery from the peroneal artery at the midpoint of the fibular and enjoys both endosteal and periosteal blood supply[3,4]. Free vascularized fibular grafting was first reported in 1975 by *Taylor et al*[5]. and its use in the upper limb by *Weiland et al*[6] in 1979. Non vascularized grafts however can be used for defects about 6cm and healing occurs by creping substitution[2].

Case report

We present the case of a 38-year-old right-hand dominant female with recurrent pain in the right wrist for 10 years and progressive swelling of the same region of 7 years duration. The pain was insidious, dull aching and non-radiating, swelling progressively increased to involve the forearm. There was no weight loss, no fever, no chronic cough, no anorexia, no prior trauma, nil exposure to irradiation, no other similar swellings, and no movement at the wrist joint. She was not a known hypertensive or diabetic with no known allergies. On examination she was not pale, anicteric and well hydrated, with significant findings in the right upper limb, swelling in the distal two-thirds of the forearm abutting at the wrist joint and measured 16 x 12 x 14cm, hard mass, non-tender, no differential warmth, immobile and attached to the skin on the summit. There was no movement at the wrist but a limited range of motion in the joints of the hand. Radial pulse was not palpable at the wrist and there was hypoaesthesia in the hand. Chest and abdominal examinations were unremarkable. Plain X-rays done revealed a ballooned-out osteolytic lesion in the distal two-thirds of the radius with disruption of the wrist joint (Fig.1). A core needle biopsy revealed a giant cell tumour and she was counselled for a single-stage wide local excision and autologous free vascularized fibular graft and stabilization with plates and screws.
The tumour was excised en-bloc with the distal two-thirds of the radius measuring 20cm in length and also a 4cm defect in the distal ulnar (Fig.3). The fibular was harvested from the contralateral leg and 20cm length was used to reconstruct the radius, 4cm for the ulnar defect and fixed proximally and distally with dynamic compression plates and arthrodesis of the wrist joint, repair of transected extensor tendons,

From the Department of Plastic and Reconstructive Surgery National Orthopaedic Hospital, Igbobi, Lagos, Nigeria. Received on September 6, 2022. Accepted on September 14, 2022. Published on September 16, 2022.

 DOI 10.5281/zenodo.7087904

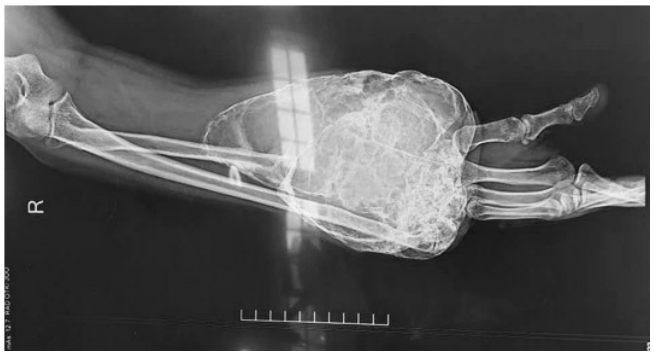

Figure 1. Plain radiograph of the right forearm.

danastomosis was done end to end with the radial vessels using proline 8/0 sutures in the mid-forearm using operating loupes with 6.0x magnification. Postoperatively she had analgesia, antibiotics and anticoagulants. She had a dehiscence of the forearm wound which healed with conservative care. There was no donor site morbidity. The patient was discharged after 3 weeks.

Discussion

Limb sparing surgery for neoplasia in the upper limb is well established with treatment outcomes for bone and soft tissue tumours dramatically improved over the past decades, therapeutic options are often determined by factors such as tumour size, location and nerve involvement.

The use of bone transport and non-vascularized fibular strut graft for replacing large bone defects have been well documented in the literature but with defects greater than 6cm, there are varying levels of success[7], as the radius and ulna are poor producers of new bone by callotasis, which may require many months for a relative small defect[8]. For larger defects, free vascularized fibular graft shows immense potential in maintaining the function of the affected limb and is

Figure 2. Pre op. Images.

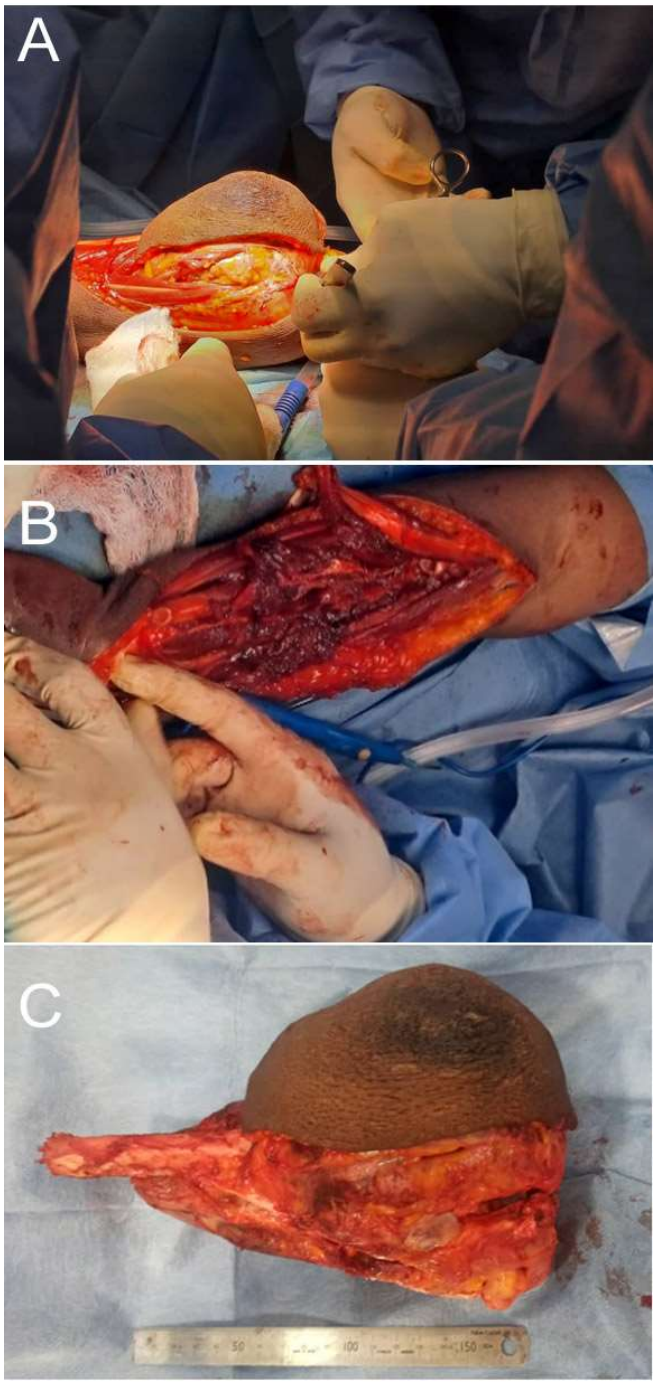

Figure 3. Intra-operative photographs.

articularly useful in younger patients[1], especially when compared to other methods like distraction osteogenesis which requires a prolonged consolidation period and often can cause discomfort[9]. The advantages of vascularized fibular grafting for large bony defects include immediate structural support, resistance to infection due to its blood supply and non-reliance on the surrounding tissue for graft incorporation.

The fibula's size and shape is very similar to the diaphysis of the radius and ulna, making it an ideal donor for the reconstruction of significant forearm bone loss[10].

DOI 10.5281/zenodo.7087904

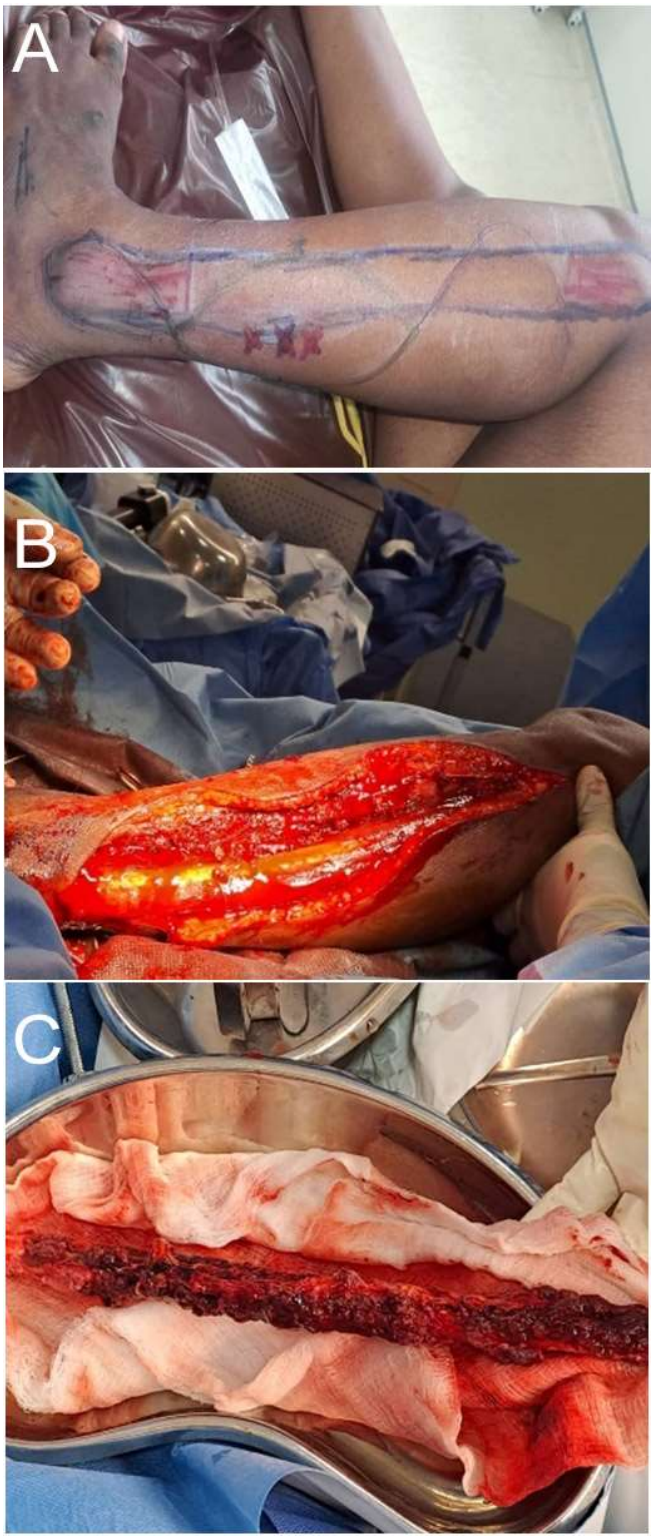

Figure 4. Harvest of the fibula flap.

In the index case, a combination of a vascularized fibular graft and a non-vascularized graft was used to reconstruct the radius and ulna respectively based on the size of the individual defects. Current advances in microsurgery in the subregion have made vascularized grafts more feasible and limb-sparing surgery following the excision of tumours possible. Single-stage reconstruction has the advantages of soft tissue coverage, prevention of scarring which may limit

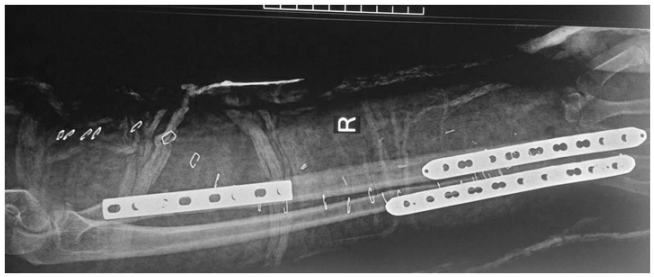

Figure 5. Immediate post operative radiographs.

Figure 6. Donor and recipient sites at 3 weeks post operatively.

microsurgical tissue transfer at a second stage, early structural stabilization with the promotion of bone union and reduction of overall healing time[4].

Conclusion

Limb sparing surgery is the mainstay in the treatment of tumours in the forearm and vascularized fibular graft has become the gold standard for managing large defects. The specific features of the fibular in similarity with the forearm bones make it an ideal and readily available choice for single-stage reconstruction in these patients. This however creates the need for more experience in vascular and microsurgical expertise in the sub-region.

Acknowledgements

Department of Burns, Plastic and Reconstructive Surgery, National Orthopaedic Hospital, Lagos.

Oncology unit, Department of Orthopaedic and Trauma Surgery, National Orthopaedic Hospital, Lagos.

Conflicts of interests

The authors declare no conflict of interest.

References

1. Gebert C, Hillmann A, Schwappach A, Hoffmann C, Hardes J, Kleinheinz J, et al. Free vascularized fibular grafting for reconstruction after tumour resection in the upper extremity. J Surg Oncol [Internet]. 2006 Aug 1;94(2):114–27. Available from: https://onlinelibrary.wiley.com/doi/10.1002/jso.20326
2. Eward WC, Kontogeorgakos V, Levin LS, Brigman BE. Free vascularized fibular graft reconstruction of large skeletal defects after tumor resection. Clin Orthop Relat Res [Internet]. 2010 Feb;468(2):590–8. Available from: https://journals.lww.com/00003086-201002000-00042
3. Orupabo F. Vascularised fibular graft.. Furo Orupabo - ISSN 1597-4292. 16(3).
4. Noaman HH. Management of Upper Limb Bone Defects Using Free Vascularized Osteoseptocutaneous Fibular Bone Graft. Ann Plast Surg [Internet]. 2013 Nov;71(5):503–9. Available from: https://journals.lww.com/00000637-201311000-00016
5. Hu QT, Jiang QW, Su GL, Shen JZ, Shen X. Free vascularized bone graft. Chin Med J (Engl) [Internet]. 1980 Nov;93(11):753–7. Available from: http://www.ncbi.nlm.nih.gov/pubmed/6775885
6. Weiland AJ, Kleinert HE, Kutz JE, Daniel RK. Free vascularized bone grafts in surgery of the upper extremity. J Hand Surg Am [Internet]. 1979;4(2):129–44. Available from: http://dx.doi.org/10.1016/S0363-5023(79)80129-X
7. Lawal Y, Garba E, Ogirima M, Dahiru I, Maitama M, Abubakar K, et al. Use of non-vascularized autologous fibula strut graft in the treatment of segmental bone loss. Ann Afr Med [Internet]. 2011;10(1):25. Available from: http://www.annalsafrmed.org/text.asp?2011/10/1/25/76571
8. Adani R, Delcroix L, Innocenti M, Marcoccio I, Tarallo L, Celli A, et al. Reconstruction of large posttraumatic skeletal defects of the forearm by vascularized free fibular graft. Microsurgery [Internet]. 2004;24(6):423–9. Available from: https://onlinelibrary.wiley.com/doi/10.1002/micr.20067
9. Sun Y, Zhang C, Jin D, Sheng J, Cheng X, Liu X, et al. Free vascularised fibular grafting in the treatment of large skeletal defects due to osteomyelitis. Int Orthop [Internet]. 2010 Mar 24;34(3):425–30. Available from: http://link.springer.com/10.1007/s00264-009-0761-x
10. Houdek M, Wagner E, Wyles C, Nanos G, Moran S. New Options for Vascularized Bone Reconstruction in the Upper Extremity. Semin Plast Surg [Internet]. 2015 Feb 4;29(01):020–9. Available from: http://www.thieme-connect.de/DOI/DOI?10.1055/s-0035-1544167

Christian Chukwudi Ojidoh
Department of Plastic and Reconstructive Surgery
National Orthopaedic Hospital, Igbobi, Lagos, Nigeria,
ojidoh@me.com

 DOI 10.5281/zenodo.7087904