Otomastoiditis as an initial manifestation of granulomatosis with polyangiitis. A case report

Alejandra Rojas Bringas M.D.
Joaquín Molina Muñoz M.D.
Alba Nalletzin Bibiano López M.D.
Jonathan René Ramírez Macías M.D.

Orizaba, Mexico

Background: Vasculitis are classified according to the type of vessels affected, characterized by the presence or absence of antibodies or markers of infection; the classification should not be confused with the diagnostic criteria, in adults the Chapel Hill nomenclature. Autoantibodies against cytoplasmic antigens expressed on neutrophil granules directed against MPO and PR3 where the relationship of PR3 with ANCA-associated small vessel vasculitis granulomatosis with polyangiitis is relevant; the presentation by systems affects ear, nose and throat 83-99%, musculoskeletal 59-77%, respiratory 64-85%, renal 65-77%, skin 33-46%, head manifestations include otic congestion, conductive hearing loss as a result of middle ear inflammation.

Keywords: Vasculitis, granulomatosis.

Case Report

Internal Medicine

OPEN ACCESS

Vasculitis associated with anti-neutrophil cytoplasm antibodies have a predisposition for small and medium caliber vessels with a predisposition for renal, nasosinusal and pulmonary involvement. Vasculitis are classified according to the type of vessels affected, characterized by the presence or absence of antibodies or markers of infection; the classification should not be confused with diagnostic criteria, in adults the Chapel Hill nomenclature is the most commonly used classification system. Autoantibodies against cytoplasmic antigens expressed in neutrophil granules directed against MPO and PR3 where the relationship of PR3 with ANCA-associated small vessel vasculitis granulomatosis with polyangiitis characterized by necrotizing granular lesions in upper or lower airway is relevant, glomerulonephritis and granulomatous vasculitis in the upper or lower airway, and it was also found that antibodies directed against proteinase 3 correlated with the existence of ANCA and this type of granulomatosis. The incidence of granulomatosis with polyangiitis is 7-14 per million population/year mainly in North America and Europe with an age range of 45-70 years with a male predilection. The exact cause has not been identified however inhalation of dust or silica are the most likely causes in 8% of patients. Infectious agents play a role in the outcome of this entity by molecular mimicry. The clinical features by specificity of ANCA-PR3 in terms of the anatomopathological specimen is a necrotizing vasculitis, granulomatous inflammation that usually affects the upper and / or lower airway, necrotizing vasculitis mainly affects small and medium caliber vessels; Respiratory involvement most commonly includes nodules, cavitation and a history of central airway disease with destructive lesions such as nasal perforation, ethmoidal erosion, saddle nose; head manifestations include otic congestion, conductive hearing loss as a result of middle ear or Eustachian tube inflammation. Oral ulcers, gingivitis and auricular chondritis are well described, although less frequent. Usually in terms of treatment, there is a better response to rituximab than to cyclophosphamide.

Case report

Male patient of 43 years of age with no pathological personal history. He reported the presence of holocranial headache of intensity 5/10, pulsatile, bilateral otalgia of 1 month of evolution of intensity 8/10 without yielding to analgesic therapy accompanied by the presence of vertigo of subjective sensation accompanied by vegetative symptoms, nausea which progresses to emesis partially yielding with antiemetic and antivertiginous. Physical examination revealed right hypoacusis, ulcer-like lesion in the posterior third of the right lateral side of the tongue, painful to palpation, friable aspect, indurated, dirty bottom, 2.5x2x1 centimetres, as well as in the ipsilateral retromolar trigone with similar characteristics conditioning difficulty in swallowing. Bilateral otoscopy with permeable and hyperaemic external auditory canals, tympanic membranes intact, bulging with apparent transmembrane collection, hammer handle norm inserted, hypomobile; rhinoscopy with block septum on the right, congestive turbinates, bloody nasal crusts; right retro auricular pain with erythematous mastoid area, pain on

From the Internal Medicine Department at Hospital General de Puebla "Dr. Eduardo Vázquez Navarro". Puebla, México. Received on September 23, 2024. Accepted on September 25, 2024. Published on September 27, 2024

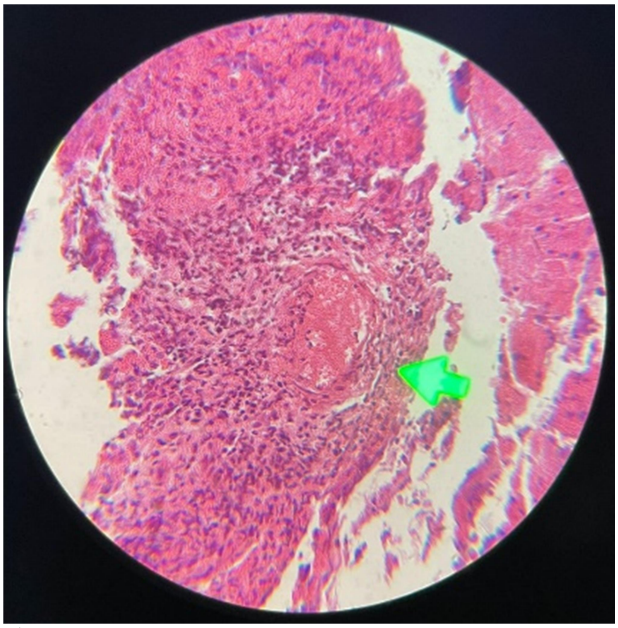

Figure 1. Biopsy of the right lateral wall of the tongue. Necrotizing granulomatous inflammation with necrotizing vasculitis. Non-keratinized stratified squamous epithelium. Cellular detritus, polymorphonuclear, histiocytes, small and medium-sized vessels with neutrophils in their wall, as well as fibrin and cellular detritus. Vessels surrounded by coagulative necrosis with multinucleated cells.

Figure 2. Saburral tongue.Right lateral side of the tongue, ulcer-like lesion, painful on palpation, friable appearance, indurated, dirty bottom, 2.5x2x1 centimeters with hemorrhagic edges and apparent fibrin.

palpation 5/10. She denies fever; pelvic limbs with asymmetric purpuric lesions, bilateral, not palpable, referring the presence of this 1 month prior to the mentioned symptomatology. Computed tomography was requested to visualize the mastoid and middle ear canal, reporting occupation of the right middle ear, as well as mastoid cells, images with similar density to soft tissues. Blood cytometry without relevant data. Antimicrobial coverage of broad spectrum based on glycopeptide and third generation cephalosporin is started, as well as biopsy of lesion in lateral wall of tongue with presence of fibrin, cellular debris, polymorphonuclear, histiocytes, and medium and small size vessels with presence of neutrophils in the vessel wall as well as fibrin and cellular detritus inside the vessels, surrounded by coagulative necrosis of the surrounding tissue with some multinucleated giant cells concluding necrotizing granulomatous inflammation with necrotizing vasculitis compatible with granulomatosis with polyangiitis. Rheumatologic studies with rheumatoid factor: 320 IU/ml and anti-neutrophil cytoplasmic antibody C (ANCA-C): 1.25U/ml, anti PR3 positive concluding small vessel vasculitis: Granulomatosis with polyangiitis.

Discussion

Vasculitis is characterized by inflammation of blood vessels generating vascular destruction histologically reflecting fibrinoid necrosis, giving the term necrotizing vasculitis with production of local symptoms depending on the site of involvement resulting in hypoperfusion, infarction and haemorrhage, as well as systemic symptoms with increased acute phase reactants. Small vessel vasculitis predominantly affects small vessels defined as small intraparenchymal arteries, arterioles, capillaries and venules, histologically with necrotizing vasculitis, with little or no immunological deposit; they can be associated with autoantibodies directed against proteins: myeloperoxidase or proteinase 3, although they are not present in all patients. As for the symptomatology, symptoms are nonspecific, inflammation of the upper or lower airway may appear at the same time as the systemic presentation or precede it by weeks, months or even years, however, a striking feature is its destructive power and its speed of involvement is very variable. Regarding the case presented, the presence of epistaxis, mucopurulent rhinorrhoea and bloody nasal crusts is uncommon, on the contrary, inflammation of the paranasal sinuses, involvement of the nasal septum which may progress to collapse and a characteristic deformity known as “saddle” is frequent. Bone erosions can also occur anywhere: paranasal sinuses, mastoid cells, hard palate and less frequently in the ocular orbit. As for the percentage of presentation by systems, it affects ear, nose and throat 83-99%, musculoskeletal 59-77%, respiratory 64-85%, renal 65-77%, skin 33-46%. Treatment is based on two stages, induction and maintenance. Induction usually lasts 3-6 months and should be maintained until remission, defined as absence of disease activity, and the maintenance stage should be maintained for at least 24 more months considering risk factors for recurrence such as the

DOI 10.5281/zenodo.13852534
Copyright 2024 © Unauthorized reproduction of this article is prohibited.

presence of PR3, pulmonary involvement or respiratory tract involvement prior to remission.

Conclusions

Granulomatosis with polyangiitis is a rare pathology with manifestations in the respiratory, musculoskeletal and respiratory system where the presence of ANCA-PR3 provides orientation to this, having a confirmation of this vasculitis according to the pathological findings: necrotizing vasculitis and granulomatous inflammation, however, a large percentage manifests with severe complications such as sepsis or alveolar haemorrhage resulting in the timely and early identification of this pathology to initiate treatment in a timely manner and achieve a significant impact on survival and improved prognosis.

Conflicts of interests

We declare no potential conflicts of interest of any of the authors in this scientific report.

Acknowledgements

We would like to acknowledge the staff involved in the management of this patient for their excellent work.

References

1. Wojciechowska, J., Krajewski, W., Krajewski, P., & Kręcicki, T. (2016). Granulomatosis with polyangiitis in otolaryngologist practice: A review of current knowledge. Clinical and Experimental Otorhinolaryngology, 9(1), 8–13.
2. Monach, P. A. (2014). Biomarkers in vasculitis. Current Opinion in Rheumatology, 26(1), 24–30.
3. Salvador, F. (2020). ANCA associated vasculitis. European Journal of Internal Medicine, 74, 18–28.
4. Trimarchi M, Sinico RA, Teggi R, Bussi M, Specks U, Meroni PL. Otorhinolaryngological manifestations in granulo-matosis with polyangiitis (Wegener's). Autoimmun Rev 2013;12:501-505.
5. Wallace ZS, Fu X, Harkness T, Stone JH, Zhang Y, Choi H. All-cause and cause-specific mortality in ANCA-associated vasculitis: overall and according to ANCA type. Rheumatology 2020; 59: 2308–15.
6. Jennette JC, Falk RJ, Bacon PA, et al. 2012 revised International chapel hill consensus conference nomenclature of vasculitides. Arthritis Rheum 2013; 65(1):1–11.
7. Geetha D, Jeferson JA (2020) ANCA-associated vasculitis: core curriculum 2020. Am J Kidney Dis 75:124–137

Joaquín Molina Muñoz
Internal Medicine Department
Hospital General de Puebla
"Dr. Eduardo Vázquez Navarro"
Puebla, México.

 DOI 10.5281/zenodo.13852534
Copyright 2024 © Unauthorized reproduction of this article is prohibited.